

# Comparison Study

## Between the diode lasers:

- MeDioStar with a single wavelength of 808 nm
- MeDioStar miXT with a fixed combination comprising two wavelengths, 808 nm and 938 nm

The aim of the study is to compare the affectivity and side effects of both lasers in half-side treatments as a basis for the FDA-Approval for hair removal (miXT).

## Requirements:

- Different skin types
- Different body regions

## Exclusion criteria:

- The use of medication that increases light sensitivity
- Cancer, precancerous or tattoos in the treated areas
- Pregnancy
- Suntanned patients or those with strongly pigmented skin
- Patients with a tendency to melasma or hyperpigmentation
- Patients with active infections in the treated areas
- Patients with an unrealistic expectancy

## Procedures:

- Photo documentation of the area to be treated in sufficient detail as to be identified in pre and post treatment pictures
- Shaving prior to treatment
- Test treatment to establish parameters and patient comfort
- Comparison photo documentation following treatment
- Completion of a protocol for each patient/treatment including:
  - Date
  - Treatment
  - Laser type
  - Laser settings
  - Treated area
  - Level of pain
  - Treatment and general observations as relevant
  - Documentation and quantitative comparisons as conducted
  - Level of patient comfort (pain) Scale 0 - 10 where 0 is no pain

## Post treatment:

Post treatment was the same in all cases

- Cool-packs (ca. 8°C) for a minimum of 5 minutes
- Sun avoidance, or use of sun-blockers between treatments or for a minimum period of 5 weeks

**1**

**Protocol – MeDioStar Diode laser (808nm) and miXT (808nm + 938nm)**

<b>Patient ID</b>		<b>Further Information</b>					Name N.K. Number 12460 Sex Female Age 30 Nationality - Afganistan	
		<b>Region</b>					Full-face	
		<b>Skin type (Fitzpatrick)</b>					3/4	
Date (2007)	Treatment	Laser type	Settings				Pain level 1-10	Remarks
			Mode	Fluence J/cm <sup>2</sup>	Imp. Time (ms)	Impulse		
09.05	Test	MiXT R	B	25	-	30	4	
		808 L	B	25	-	29	4	
16.05	1	MiXT R	Pro2	25	100	220	3	
		808 L	Pro2	25	100	235	3	
20.06	2	MiXT R	Pro2	30	100	263	4	
		808 L	Pro2	30	100	243	4	
25.07	3	MiXT R	Pro2	30	140	215	4	
		808 L	Pro2	30	140	232	4	

This patient showed a rapid improvement not only in hair reduction but also in folliculitis. No significant difference between areas treated with either laser. Lighter facial hair was quickly removed on the cheeks whilst the stronger growth on the chin requires further treatment. The hair in the frontal chin region is still very strong on both sides although the patient felt they were not so bristly. The neck and jaw regions with a lighter hair growth are appreciably better.

Measurements/Photos/Further Documentation			
Date	Region	Picture/Doc/Hair count (/cm <sup>2</sup> )	Remarks
09.05	Full-face	Frontal chin	Initial condition
25.07	Full-face	Frontal chin	Condition following 3 full treatments

<b>1</b>	N.K. 12460	<b>Remarks</b>	Initial condition
			
			
<p style="text-align: center;"> <span data-bbox="512 1915 884 1951">Diode Mix 808 + 938 nm</span>   <span data-bbox="987 1915 1294 1951">Diode Laser 808 nm</span> </p> <p style="text-align: center;"><b>Diode miXT (808 + 938) Patient right side – Diode (808) Patient left side</b></p>			

Patient ID		Name Number Sex Age Further Information					S.P. 16368 Female 25 Nationality - German	
		Region Skin type (Fitzpatrick)					Neck 2	
Date (2007)	Treatment	Laser type	Settings				Pain level 1-10	Remarks
			Mode	Fluence J/cm <sup>2</sup>	Imp. Time (ms)	Impulse		
11.05	Test	MiXT R	B	30	-	22	0	
		808 L	B	30	-	20	0	
21.05	1	MiXT R	Pro2	30	100	220	2	
		808 L	Pro2	30	100	235	2	
22.06	2	MiXT R	Pro2	30	140	263	3	
		808 L	Pro2	30	140	243	3	
19.07	3	MiXT R	Pro2	30	140	215	3	
		808 L	Pro2	30	140	232	3	
Hypertrichosis since age 14 shaved daily. Hormone status in normal range. An acceptable result after three treatments but more are required. No significant difference between areas treated with either laser.								

Measurements/Photos/Further Documentation			
Date	Region	Picture/Doc/Hair count (/cm <sup>2</sup> )	Remarks
11.05	Neck	Neck right side	Initial condition
11.05		Neck left side	Initial condition
19.07		Neck right side	Condition following 3 full treatments
19.07		Neck left side	Condition following 3 full treatments
	Neck	Initial Hair count – right side	Approx. 26 hairs
		Final hair count – right side	Approx 6 hairs
		Initial Hair count – left side	Approx. 28 hairs
		Final hair count – left side	Approx. 9 hairs

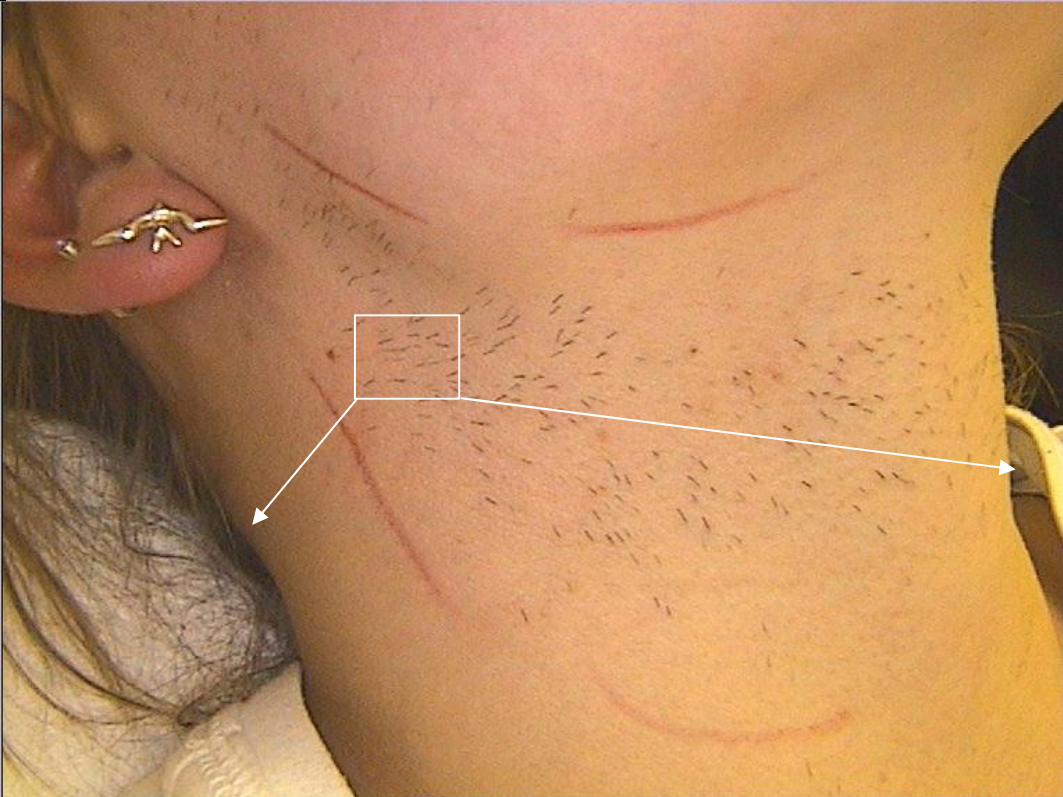

**2**

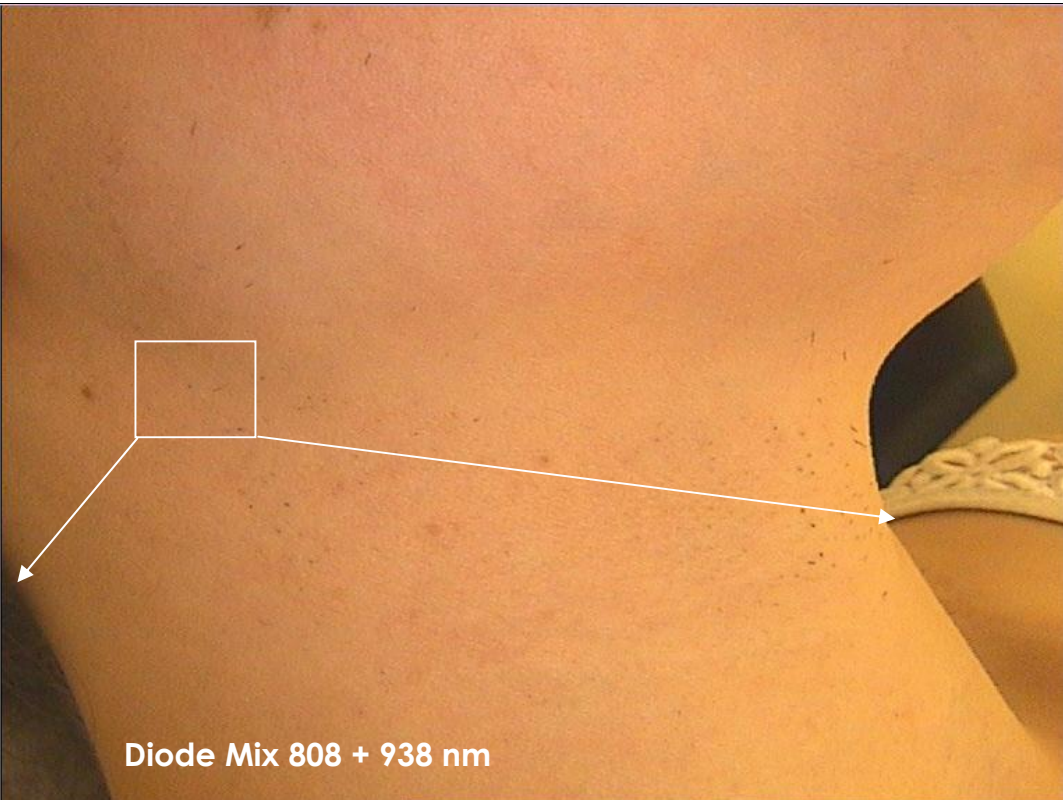
S.P.16368

**Remarks**

Neck right side



**Hair count – Approx. 26 hairs**



**Diode Mix 808 + 938 nm**

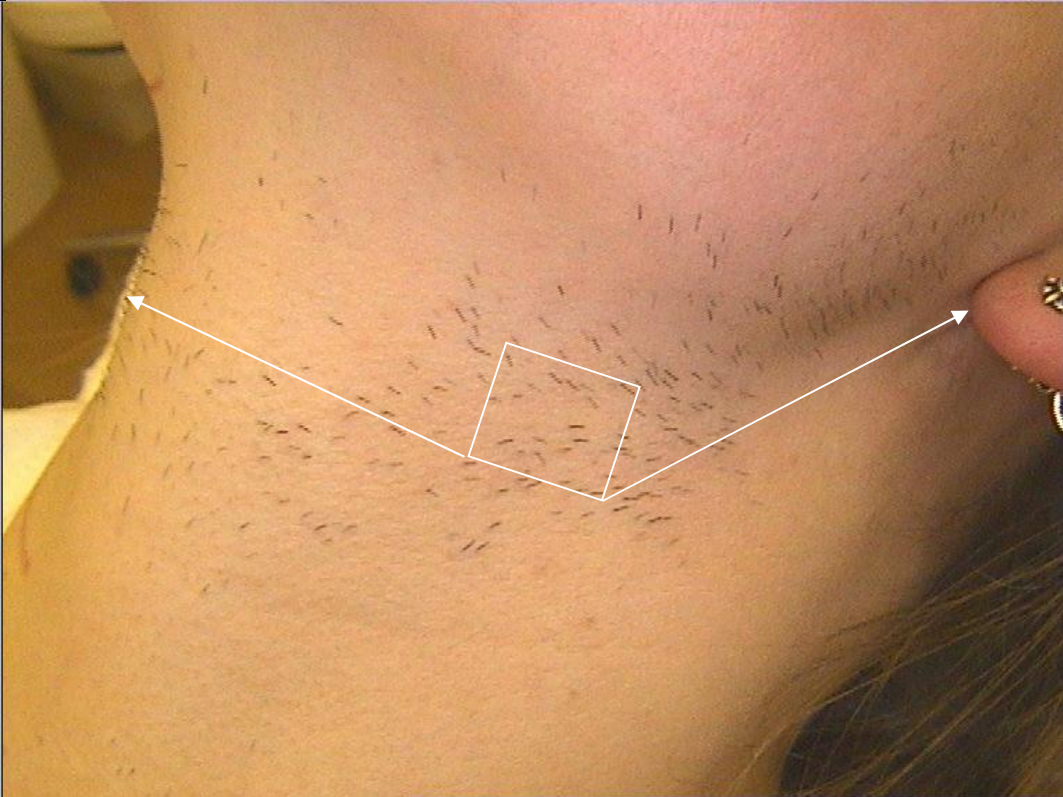**Hair count following treatments with diode miXT (808 + 938) – Approx. 6 hairs**

**2**

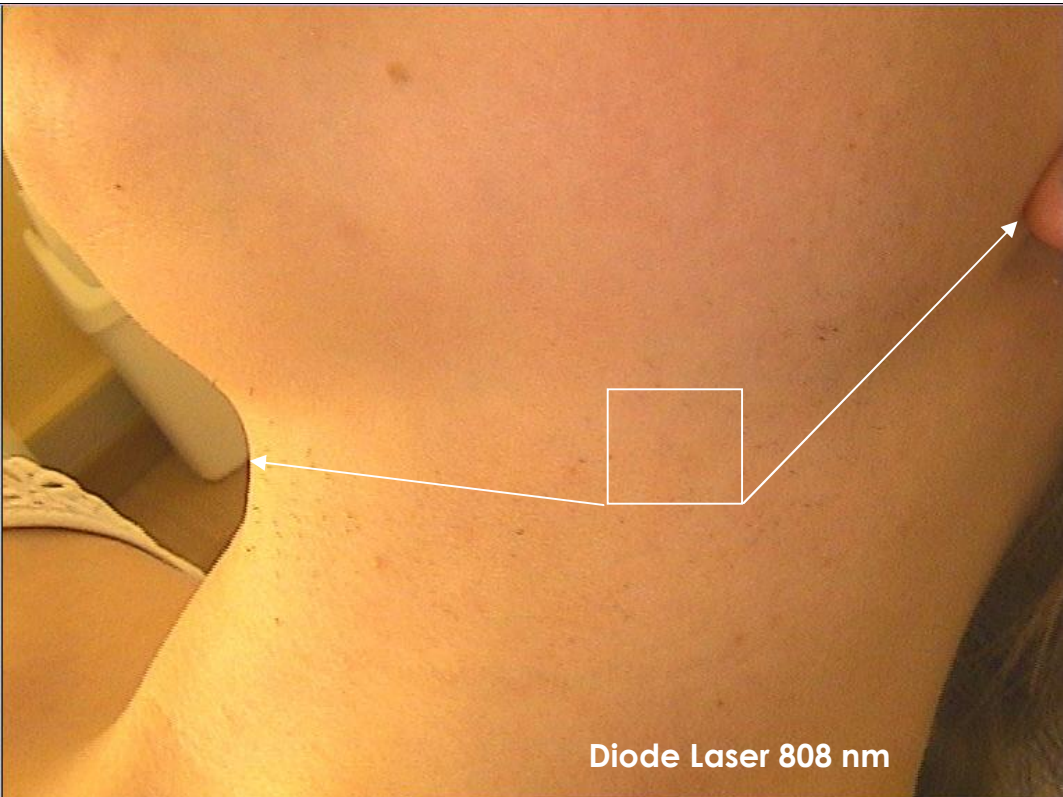
S.P.16368

**Remarks**

Neck right side



**Hair count – Approx. 28 hairs**



**Diode Laser 808 nm**

**Hair count following treatments with diode (808) – Approx. 9 hairs**

**3**

**Protocol – MeDioStar Diode laser (808nm) and miXT (808nm + 938nm)**

<b>Patient ID</b>		<b>Name</b> S.S. <b>Number</b> 25989 <b>Sex</b> Female <b>Age</b> 35 <b>Further Information</b> Transsexual patient with hormone therapy						
		<b>Region</b> Full-face <b>Skin type (Fitzpatrick)</b> 2						
Date (2007)	Treatment	Laser type	Settings				Pain level 1-10	Remarks
			Mode	Fluence J/cm <sup>2</sup>	Imp. Time (ms)	Impulse		
02.06	Test	MiXT R	B	30	-	20	8	
		808 L	B	30	-	20	8	
09.06	1	MiXT R	B	30	-	102	4	Emla – topical anaesthetic
		808 L	B	30	-	98	4	
07.07	2	MiXT R	B	30	-	96	4	
		808 L	B	30	-	110	4	

This transsexual patient has been in treatment for hair removal for several years. Last previous treatment was for 16 months. Hormone treatment is usual for a patient of this type. This patient is exceptionally pain sensitive. Basic treatment mode was used for all treatments, increased impulse times tend to increase the level of pain. No significant difference between areas treated with either laser after 2 treatments.

Measurements/Photos/Further Documentation			
Date	Region	Picture/Doc/Hair count (/cm <sup>2</sup> )	Remarks
02.06	Neck	Neck right side	Initial condition
02.06		Neck left side	Initial condition
07.07		Neck right side	Condition following two treatments
07.07		Neck left side	Condition following two treatments
	Neck	Initial Hair count – right side	Approx. 32 hairs
		Final hair count – right side	Approx. 15 hairs
		Initial Hair count – left side	Approx. 42 hairs
		Final hair count – left side	Approx. 24 hairs

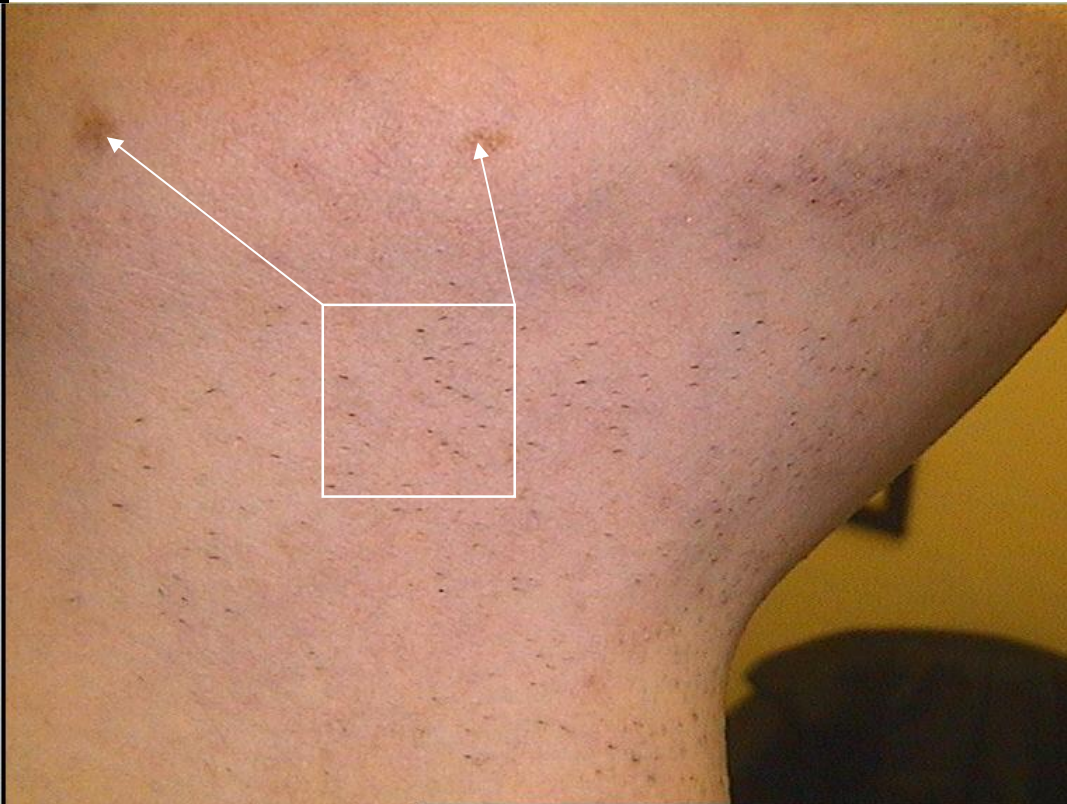

**3**

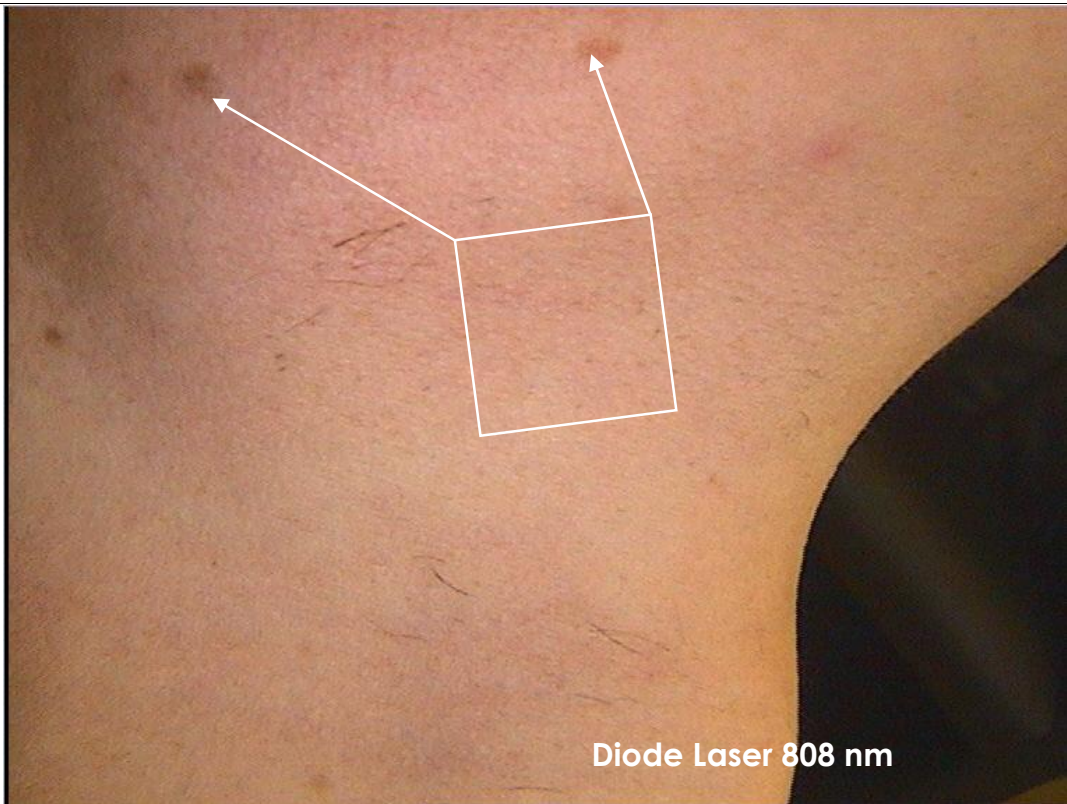S.S. 25989

**Remarks**

Neck/Chin – right side



**Hair count – Approx. 32 hairs**



**Diode Laser 808 nm**

**Hair count – Approx. 15 hairs**

<b>3</b>	S.S. 25989	<b>Remarks</b>	Neck/chin – left side
			
<p style="text-align: center;"><b>Hair count – Approx. 42 hairs</b></p>			

			
<p style="text-align: center;"><b>Hair count – Approx. 24 hairs</b></p>			

**4**

**Protocol – MeDioStar Diode laser (808nm) and miXT (808nm + 938nm)**

<b>Patient ID</b>		<b>Further Information</b>					<b>Name</b> A.V. <b>Number</b> 16584 <b>Sex</b> Female <b>Age</b> 52	
		<b>Region</b>					Full-face	
		<b>Skin type (Fitzpatrick)</b>					2/3	
Date (2007)	Treatment	Laser type	Settings				Pain level 1-10	Remarks
			Mode	Fluence J/cm <sup>2</sup>	Imp. Time (ms)	Impulse		
28.05	Test	MiXT R	B	30	-	45	2	
		808 L	B	30	-	56	2	
01.06	1	MiXT R	B	30	100	136	3	
		808 L	B	30	100	122	3	
06.07	2	MiXT R	Pro2	30	140	141	5	
		808 L	Pro2	30	140	138	5	
03.08	3	MiXT R	Pro2	30	140	136	4	
		808 L	Pro2	30	140	141	4	

This patient has hypertrichosis for over 10 years, since the start of her menopause. Patient suffers from severe scarring due to folliculitis as a result of plucking the hairs. It is of note that with this patient not only is there a significant reduction of hair but also a softer definition of the scarring. Folliculitis is considerably reduced due to lack of plucking.

Although in the initial picture the patient left side would appear to have more hair than the right side this is primarily due to the patients habit of plucking one area at a time. Over a period of 4 months and a reduction of plucking by the patient both sides would appear to be equally balanced.

Measurements/Photos/Further Documentation			
Date	Region	Picture/Doc/Hair count (/cm <sup>2</sup> )	Remarks
28.05	Full-face	Frontal chin and neck	Initial condition
03.08	Full-face	Chin and cheek right side	Condition following 3 treatments
03.08	Full-face	Chin and cheek Left side	Condition following 3 treatments

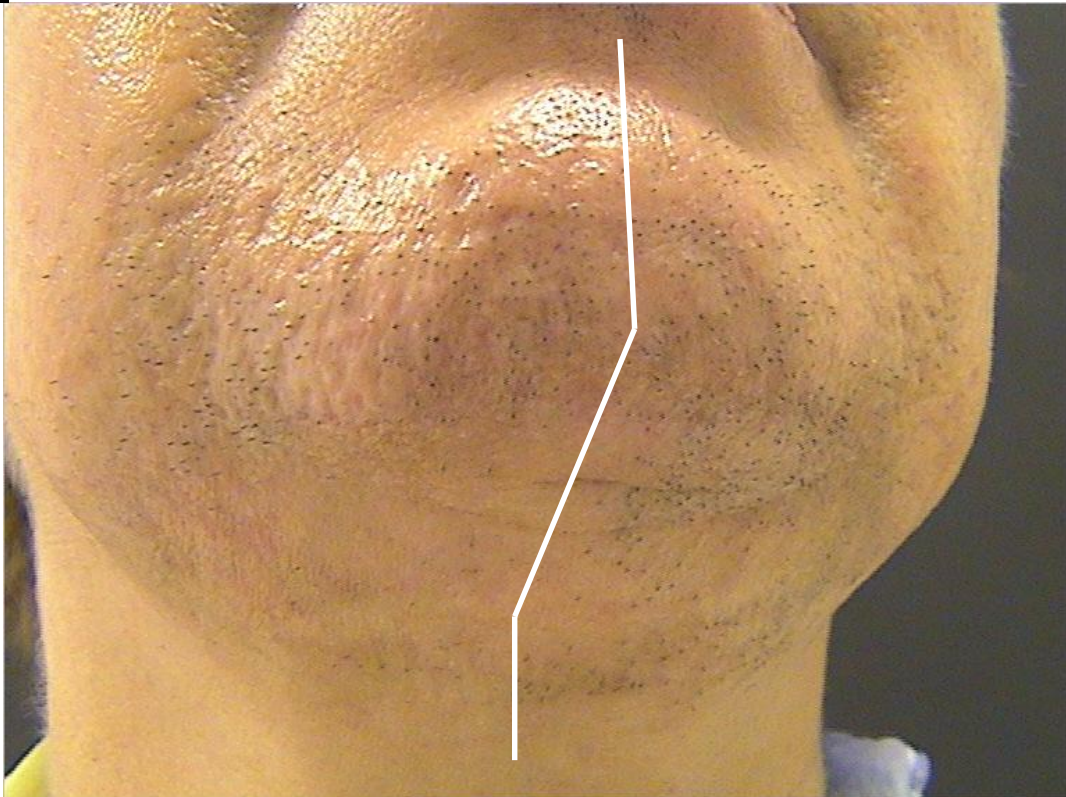

**4**

A.V. 16584

**Remarks**

Hypertrichosis and folliculitis generated scaring

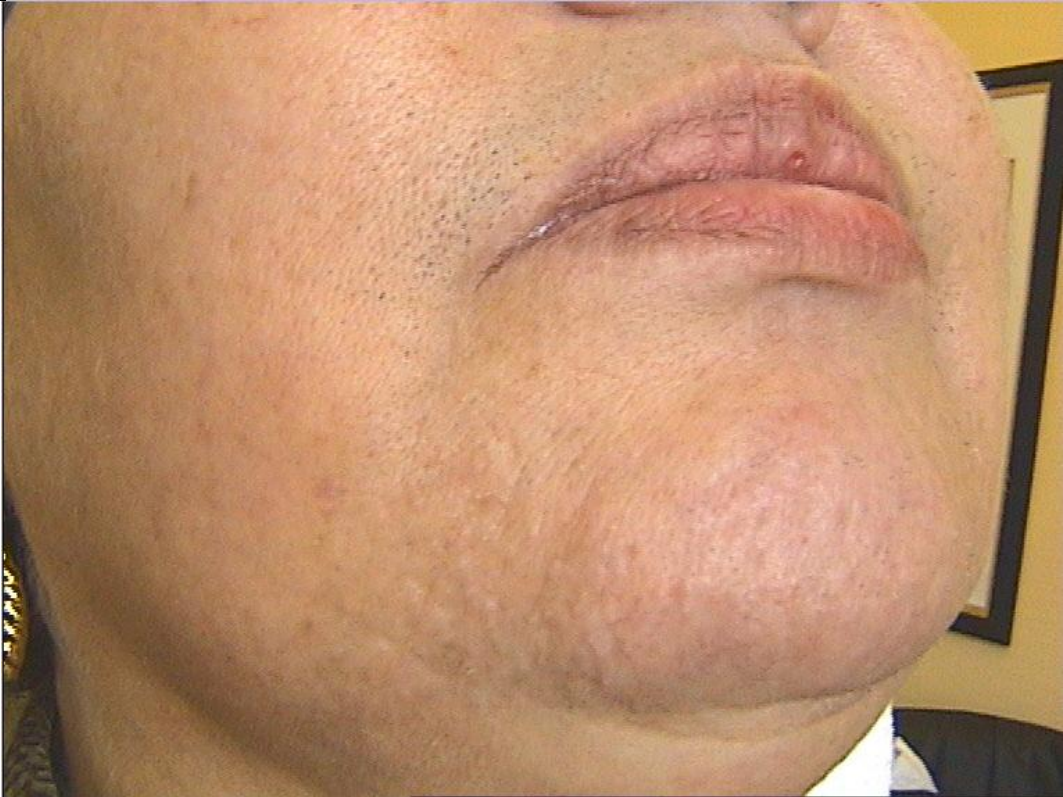

**Initial condition – Treatment - Diode miXT (808 + 938) Patient right side – Diode (808) Patient left side**

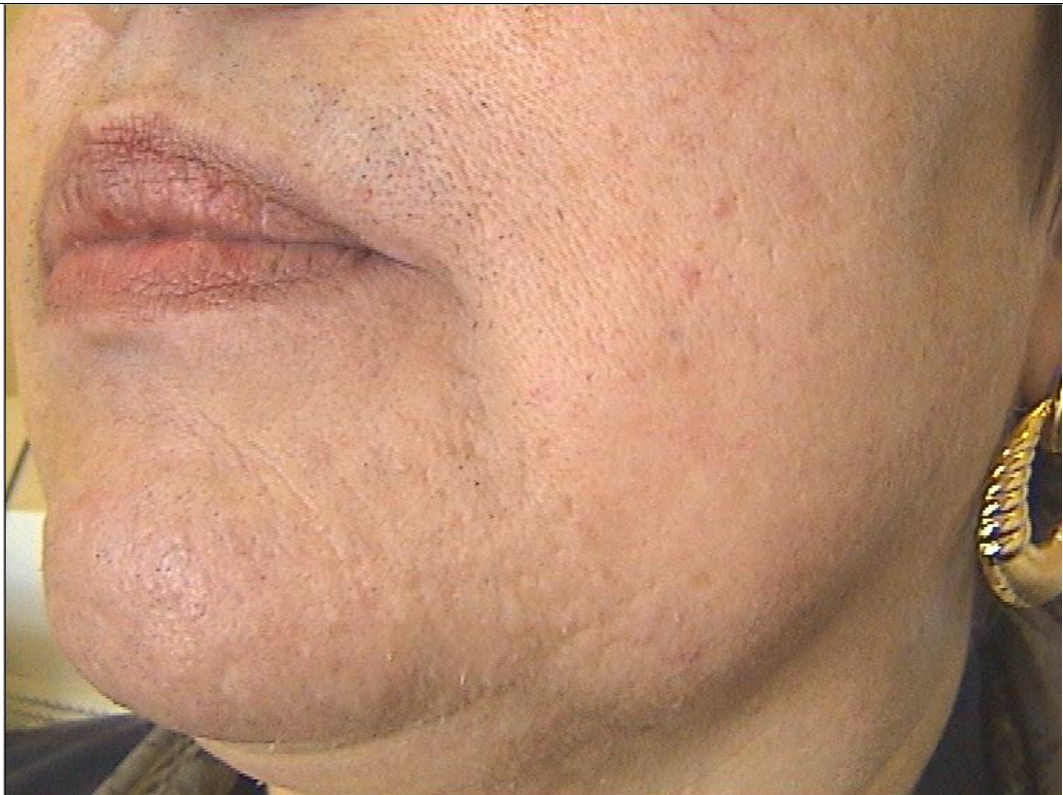**4**

A.V. 16584

**Remarks**



**Right side following 3 treatments with diode miXT (808 + 938)**



**Left side following 3 treatments with diode (808)**



**5**

**Protocol – MeDioStar Diode laser (808nm) and miXT (808nm + 938nm)**

<b>Patient ID</b>		<b>Further Information</b>					<b>Name</b> S.W. <b>Number</b> 16690 <b>Sex</b> Female <b>Age</b> 36	
		<b>Region</b>					Small bikini area	
		<b>Skin type (Fitzpatrick)</b>					2	
Date (2007)	Treatment	Laser type	Settings				Pain level 1-10	Remarks
			Mode	Fluence J/cm <sup>2</sup>	Imp. Time (ms)	Impulse		
18.05	1	MiXT R	B	30	-	87	3	No test area due to small treatment area. Test treatment is treatment 1
		808 L	B	30	-	78	3	
15.06	2	MiXT R	Pro2	30	100	104	3	
		808 L	Pro2	30	100	110	3	
13.07	3	MiXT R	Pro2	30	140	123	2	
		808 L	Pro2	30	140	114	2	
10.08	4	MiXT R	Pro2	30	140	90	2	
		808 L	Pro2	30	140	93	2	

Measurements/Photos/Further Documentation			
Date	Region	Picture/Doc/Hair count (/cm <sup>2</sup> )	Remarks
18.05	Bikini	Bikini frontal	Initial condition
10.08	Bikini	Bikini frontal	Condition following 4 treatments

**5**

S.W. 16690

**Remarks**



**Initial condition – Treatment - Diode miXT (808 + 938) Patient right side – Diode (808) Patient left side**



**Result following 4 treatments - Diode miXT (808 + 938) Patient right side – Diode (808) Patient left side**

# Conclusions

## **Evaluation of the results:**

Despite the slightly reduced level of absorption of the wavelength 938 in melanin there were in all aspects of treatment no notable differences observed between areas treated with either laser, neither in consideration of effective hair removal or patient discomfort. Differences in both qualitative (visual and patients personal feelings) and quantitative measurements are minimal and can in our opinion be ignored as statistically insignificant.

## **Side effects:**

A slight redness (erythema) of the treated area and light oedema around the hair follicles are normal following laser hair removal. There were no cases of hyper- or hypopigmentation, scabbing, or scarring. None of the patients felt discomfort following the treatments except for a light warm feeling in the treated areas. One of the patients was exceptionally pain sensitive.

Treatments, observations and Documentation were conducted by:

Dr. Paul Wood  
Dr. Ulrike Elvers

Proderma – Hautzentrum in Bad Homburg  
Schwedenpfad 2  
D-61348 Bad Homburg